

# Pallidal Deep Brain Stimulation Reduces Sensorimotor Cortex Activation in Focal/Segmental Dystonia

Andrea Greuel, MD,<sup>1</sup> K. Amande M. Pauls, MD, PhD,<sup>2,3,4</sup> Anne Koy, MD,<sup>5</sup> Martin Südmeyer, MD,<sup>6</sup> Alfons Schnitzler, MD,<sup>7</sup> Lars Timmermann, MD,<sup>1,8</sup> Gereon R. Fink, MD,<sup>9,10</sup> and Carsten Eggers, MD<sup>1,8\*</sup>

<sup>1</sup>Department of Neurology, University Hospital of Giessen and Marburg, Marburg, Germany

<sup>2</sup>Department of Neurology, Helsinki University Central Hospital, Helsinki, Finland

<sup>3</sup>Department of Clinical Neurosciences (Neurology), University of Helsinki, Helsinki, Finland

<sup>4</sup>BioMag Laboratory, Helsinki University Hospital Medical Imaging Center, University of Helsinki and Helsinki University Hospital, Helsinki, Finland

<sup>5</sup>Department of Pediatrics, Faculty of Medicine and University Hospital Cologne, University of Cologne, Cologne, Germany

<sup>6</sup>Department of Neurology, Ernst-von-Bergmann Klinikum, Potsdam, Germany

<sup>7</sup>Institute of Clinical Neuroscience and Medical Psychology, Department of Neurology, Medical Faculty, Heinrich-Heine-University Düsseldorf, Düsseldorf, Germany

<sup>8</sup>Center for Mind, Brain and Behavior, Universities Marburg and Giessen, Marburg, Germany

<sup>9</sup>Department of Neurology, Faculty of Medicine and University Hospital Cologne, University of Cologne, Cologne, Germany

<sup>10</sup>Cognitive Neuroscience, Institute of Neuroscience and Medicine (INM-3), Research Center Jülich, Jülich, Germany

**ABSTRACT: Background:** Although deep brain stimulation of the globus pallidus internus (GPI-DBS) is an established treatment for many forms of dystonia, including generalized as well as focal forms, its effects on brain (dys-)function remain to be elucidated, particularly for focal and segmental dystonia. Clinical response to GPI-DBS typically comes with some delay and lasts up to several days, sometimes even weeks, once stimulation is discontinued.

**Objective:** This study investigated how neural activity during rest and motor activation is affected by GPI-DBS while excluding the potential confound of altered feedback as a result of therapy-induced differences in dystonic muscle contractions.

**Methods:** Two groups of patients with focal or segmental dystonia were included in the study: 6 patients with GPI-DBS and 8 without DBS (control group). All 14 patients had cervical dystonia. Using H<sub>2</sub><sup>15</sup>O PET, regional cerebral blood flow was measured at rest and during a motor task performed with a nondystonic hand.

**Results:** In patients with GPI-DBS (stimulation ON and OFF), activity at rest was reduced in a prefrontal network,

and during the motor task, sensorimotor cortex activity was lower than in patients without DBS. Within-group contrasts (tapping > rest) showed less extensive task-induced motor network activation in GPI-DBS patients than in non-DBS controls. Reduced sensorimotor activation amounted to a significant group-by-task interaction only in the stimulation ON state.

**Conclusions:** These findings support previous observations in generalized dystonia that suggested that GPI-DBS normalizes dystonia-associated sensorimotor and prefrontal hyperactivity, indicating similar mechanisms in generalized and focal or segmental dystonia. Evidence is provided that these effects extend into the OFF state, which was not previously demonstrated by neuroimaging. © 2020 The Authors. *Movement Disorders* published by Wiley Periodicals, Inc. on behalf of International Parkinson and Movement Disorder Society.

**Key Words:** GPI-DBS; dystonia; H<sub>2</sub><sup>15</sup>O PET; botulinum toxin

This is an open access article under the terms of the Creative Commons Attribution-NonCommercial-NoDerivs License, which permits use and distribution in any medium, provided the original work is properly cited, the use is non-commercial and no modifications or adaptations are made.

\*Correspondence to: Dr. Carsten Eggers, Department of Neurology, University Hospital of Giessen and Marburg, Baldingerstraße, 35033 Marburg, Germany; E-mail: Carsten.Eggers@uk-gm.de

**Relevant conflicts of interests/financial disclosures:** A.G., K.A.M.P., A.K., and G.R.F. have nothing to disclose. M.S. has received speaker's fees and/or honoraria for consultancy by Medtronic, Abbott, Boston Scientific. A.S. received speaking honoraria from Medtronic Inc, Boston Scientific, Abbott/SJM. L.T. received

payments as a consultant for Medtronic Inc and Boston Scientific and received honoraria as a speaker on symposia sponsored by Medtronic, Boston Scientific, and Abbott. C.E. received speaker's honoraria from Medtronic Inc.

**Funding agency:** This study was funded by a grant from the University of Cologne.

**Received:** 11 October 2019; **Revised:** 2 December 2019; **Accepted:** 8 December 2019

**Published online 10 January 2020 in Wiley Online Library (wileyonlinelibrary.com). DOI: 10.1002/mds.27970**

Deep brain stimulation (DBS) of the bilateral internal pallidum (globus pallidus internus [GPi]) has been established as an effective therapy for generalized and segmental, idiopathic, genetic, or acquired dystonia,<sup>1-4</sup> with sustained efficacy documented for up to 10 years.<sup>5,6</sup> Focal dystonias can be treated with GPi-DBS when botulinum toxin (BTX) treatment is unsuccessful or infeasible.<sup>7-9</sup>

Dystonia is considered to be a system disorder caused by large-scale network dysfunction in cortico-subcortical circuits,<sup>10-14</sup> which can arise from various pathophysiological pathways.<sup>15,16</sup> Functional neuroimaging studies report alterations—predominantly increased activity—in brain regions directly and indirectly related to motor control. For example, studies of regional cerebral blood flow (rCBF) indicated hyperactivity in primary sensorimotor cortices (SMC; M1 and S1), premotor and supplementary motor areas (SMA), as well as the cerebellum in patients with genetically determined,<sup>17</sup> idiopathic,<sup>18,19</sup> task-specific,<sup>20</sup> and acquired<sup>3</sup> dystonia. A meta-analysis found that task-related activation was increased in M1, S1, and the inferior parietal cortex (IPC) and decreased in the (pre-)SMA and subcortical motor regions in idiopathic dystonia.<sup>21</sup>

Sensorimotor integration and higher order motor planning play essential roles in the pathophysiology of dystonia,<sup>10,22</sup> with neuroimaging correlates such as hyperactivity in S1,<sup>23,24</sup> the IPC,<sup>17,21,25,26</sup> and the anterior cingulate (ACC) and dorsolateral prefrontal (DLPFC) cortices in generalized idiopathic,<sup>18</sup> genetic,<sup>17,25</sup> acquired,<sup>3</sup> and focal dystonia.<sup>26,27</sup>

Sensorimotor hyperactivity has also been described in relation to body parts that are unaffected by dystonia<sup>15,28,29</sup> as well as in unaffected relatives of patients with genetically determined dystonia,<sup>30,31</sup> suggesting the presence of a subclinical endophenotype, that is, a general loss of inhibition as a predisposition for the development of dystonic symptoms.<sup>16,32</sup> In contrast to hyperactivity related to dystonic movements, which may partially be secondary to abnormal sensorimotor feedback, these are more direct correlates of the underlying pathology. Studying unaffected body parts may, therefore, provide essential insights about primary changes in dystonia-related brain activity.<sup>15,33</sup>

To date, the mechanisms of action of GPi-DBS in dystonia remain elusive. The full clinical benefit is typically reached only after several months and is accompanied by neurophysiological changes in the primary motor cortex.<sup>34</sup> In parallel with an improvement of dystonic symptoms, GPi-DBS reduces preoperatively increased motor cortical excitability and synaptic plasticity to physiological levels.<sup>35</sup> After years of effective stimulation, the clinical effects may last for days or weeks after stimulation is discontinued.<sup>36</sup> These findings imply a gradual reorganization process induced by GPi-DBS that corrects imbalances in sensorimotor circuits.<sup>10</sup>

A handful of studies examined the effect of GPi-DBS on rCBF in generalized idiopathic<sup>25,37,38</sup> and acquired dystonia.<sup>3,4</sup> They reported reduced resting activity<sup>3,4,25,38</sup> and task activation<sup>3,37</sup> in M1, the SMA, and/or the ACC. Activation of the DLPFC and other prefrontal regions was found to be decreased during the performance of motor tasks.<sup>3,25,37</sup> A pilot study of GPi-DBS in cervical dystonia mentioned in a review<sup>11</sup> reported similar findings, but the details were not published. In previous studies, the OFF state was considered to represent an absence of DBS, and if a motor task was performed, usually a dystonic hand was used.

The first-line treatment for focal dystonia is peripheral denervation of dystonic muscles using BTX. Its effects on brain activity have been studied with varying results: motor network activation was either decreased,<sup>39</sup> increased,<sup>40</sup> or unchanged,<sup>41</sup> while prefrontal regions were not affected.

The current study investigated the effect of chronic GPi-DBS on brain activity in focal and segmental dystonia. In contrast to previous studies, a matched control group of dystonic patients without DBS was included. The hand performing the motor task was not affected by dystonia, and the time since DBS surgery was considerably longer than previously reported. We hypothesized that in dystonia patients treated with GPi-DBS, rCBF would be reduced in primary sensorimotor and prefrontal cortices, as a reduction of hyperactivity in M1, the DLPFC, and the ACC was previously observed in GPi-DBS, but not after BTX.

## Methods

### Participants

A total of 14 patients with primary focal or segmental dystonia (6 with GPi-DBS, 8 without DBS treated with BTX [control group]) were recruited from the Departments of Neurology at the University Hospitals of Cologne and Düsseldorf. Group characteristics were analyzed in SPSS 24 (IBM Corporation, Armonk, NY). The mean time since DBS surgery was  $21.8 \pm 13.2$  months, and the surgery had been performed at University Hospital of Cologne ( $n = 4$ ) or University Hospital of Düsseldorf ( $n = 2$ ). The DBS patients did not receive any BTX injections, and none of the patients (DBS and BTX) were treated with additional antidystonic medication. BTX patients were examined under effective BTX therapy between 2 weeks and 2 months since the last injection.<sup>42</sup> The groups did not differ significantly in terms of demographics, distribution of dystonic symptoms, or patient history; individual patient information is listed in Table 1. All of the patients with hand dystonia had writer's cramp only affecting the dominant (right) hand. Formal assessments were only available for DBS patients, where the Burke-Fahn-Marsden Dystonia Rating Scale

TABLE 1. Patient details

Subject	Sex	Age	Disease Duration, y	Type of Dystonia	Dystonic Symptoms	More Affected Side	Tapping Side	SMC Activation, SPM T value
BTX 1	M	48	9.5	Focal	Torticollis to R, retrocollis	NA	R	8.36
BTX 2	F	68	15.0	Segmental	Blepharospasm, oromandibular dystonia, torticollis to R	NA	R	5.25
BTX 3	M	70	30.0	Segmental	Laterocollis R, head tremor, writer's cramp R	R	L	6.80
BTX 4	F	69	4.0	Focal	Torticollis to R	R	L	9.59
BTX 5	F	47	12.0	Focal	Torticollis to L	NA	R	5.55
BTX 6	F	55	16.0	Segmental	Torticollis to L, shoulder elevation R, writer's cramp R	R	L	5.40
BTX 7	M	60	15.0	Focal	Retro-laterocollis L	L	R	7.09
BTX 8	M	65	10.0	Focal	Retro-laterocollis R, head tremor	R	L	5.14
Mean	—	60.4 ± 9.4	13.9 ± 7.6	—	—	—	—	6.65 ± 1.64
Subject	Sex	Age	Disease Duration, y	Type of Dystonia	Dystonic Symptoms	More Affected Side	Tapping Side	SMC Activation, SPM T Value pre-/post-DBS
DBS 1	F	58	19.0	Focal	Torticollis to R	L	R	5.62/4.41
DBS 2	F	58	39.5	Segmental	Head tremor, writer's cramp R	R	L	4.20/5.25
DBS 3	M	70	16.0	Segmental	Torticollis to L, writer's cramp R	R	L	4.75/3.43
DBS 4	M	64	5.5	Focal	Torticollis to R	R	L	4.71/5.45
DBS 5	M	72	7.0	Focal	Laterocollis R, head tremor	R	L	5.31/4.65
DBS 6	M	61	6.5	Segmental	Blepharospasm, oromandibular dystonia, laterocollis R	R	L	7.09/7.60
Mean	—	64.1 ± 5.9	15.6 ± 13.0	—	—	—	5.28 ± 1.02/5.13 ± 1.40	4.8 ± 3.1/2.1 ± 1.2

<sup>a</sup>Tremor is not rated on the BFMDRS, but improvement was clearly observed.

<sup>b</sup>For this patient only the presurgical rating could be retrieved; he was not considered for calculating means (pre-DBS mean with this patient = 5.7 ± 3.5).

SMC, primary sensorimotor cortex; SPM, statistical parametric mapping; BTX, botulinum toxin; DBS, deep brain stimulation; M, male; F, female; NA, not applicable; R, right; L, left; BFMDRS, Burke-Fahn-Marsden Dystonia Rating Scale.

was performed before and after surgery. None of the patients showed signs of neurological comorbidity or combined dystonia. The treatment effects of DBS and BTX were judged as satisfactory by all patients and their movement disorder neurologists. The study was approved by the local medical ethics board (approval number 08-246) and registered with the German Clinical Trials Register (DRKS, Trial-ID 00003137). Written informed consent was obtained from each participant per the Declaration of Helsinki.

### Experimental Design

Regional cerebral blood flow was measured using  $H_2^{15}O$  PET at rest and during an externally cued finger tapping task, paced by a 1 Hz metronome that played during both task and rest conditions. Patients with GPi-DBS underwent 2 scanning sessions, 1 in the ON state and 1 after 12 hours OFF DBS. In each session, 3 rCBF-PET scans were recorded per condition, resulting in 6 scans per session, and their order was fixed but appeared randomized to the patient.

Tapping was performed with the index finger of the unaffected hand if patients had cervico-brachial dystonia. In some patients with focal cervical dystonia, the neck muscles were more hyperactive on 1 side than on the other, thus a more affected side could be determined (see Table 1), and the hand of the less affected side was used for tapping. If a more affected side could not be determined, tapping was performed with the right hand. Based on these criteria, 9 patients (4 BTX, 5 DBS) used their left hand, and the remaining 5 (4 BTX, 1 DBS) used their right hand for the tapping task.

### PET Image Acquisition

Imaging was performed on a CTI/Siemens ECAT EXACT HR+ PET (Knoxville, TN) scanner using  $H_2^{15}O$  to trace cerebral blood flow. The participants lay comfortably in a supine position in the quiet and dimly lit scanner room. A vacuum cushion was used to restrict head movement. Following a transmission scan for attenuation correction, 370 megabecquerel (MBq)  $H_2^{15}O$  were injected; acquisition started after a commonly used delay of 10 seconds after injection<sup>43,44</sup> and continued for 60 seconds per scan, recording 47 slices consisting of  $128 \times 128$  pixels (voxel size:  $2.2 \times 2.2 \times 3.2$  mm  $x \times y \times z$ , dimensions:  $128 \times 128 \times 47$  voxels  $x \times y \times z$ ). Between scans, there was an 8-minute break before the next injection. Patients' behavior during scanning was monitored visually by 2 people, and all participants performed the task as instructed without notable amounts of observable additional movement.

### Data Processing and Analysis

The scans of patients who used their right hand in the motor task were flipped along the  $x$  axis. Thus, the

hemispheres are referred to as ipsilateral and contralateral to the hand used for tapping.

Preprocessing and statistical analyses were performed in SPM12 ([www.fil.ion.ucl.ac.uk/spm/software/spm12](http://www.fil.ion.ucl.ac.uk/spm/software/spm12)). The images from each session were realigned to their mean image, and for DBS patients, the scans from DBS ON and OFF sessions were then coregistered. Each patient's mean image was spatially normalized to MNI space using the SPM PET template, adopting the template's resolution (voxel size 2 mm cubic, dimensions:  $91 \times 109 \times 91$  voxels). The resulting transformation was applied to individual scans. Finally, a Gaussian smoothing kernel of 10 mm (full width at half maximum) was applied.

To create statistical parametric maps,<sup>45</sup> a flexible factorial design was set up in SPM12 with the factors group, DBS, task, and subject, with 3 levels for DBS (no DBS, ON state, and OFF state) and a DBS-by-task interaction. An explicit mask was included to only consider voxels inside the intracranial volume, and global normalization by proportional grand mean scaling was applied using default parameters. Global signals were similar between groups. The same design was set up with a subject-by-task interaction to visualize appropriate motor activation in individual participants for quality control.

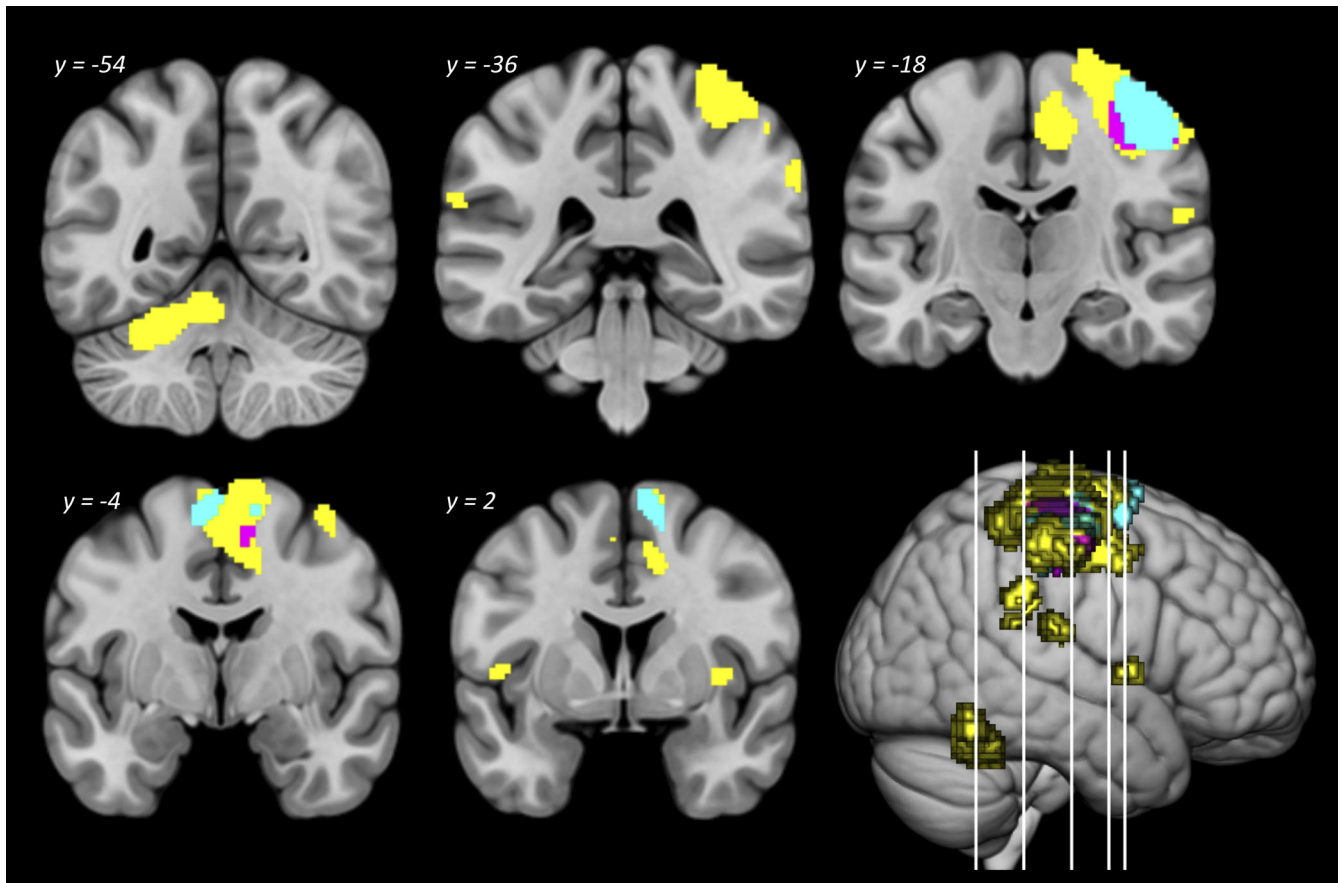
Motor activation (tapping > rest) was measured at the participant and group levels, followed by between-group analyses. To assess the effect of GPi-DBS on both resting brain activity and task-associated activation, rCBF was compared between groups (DBS ON vs. BTX; DBS OFF vs. BTX) at rest and during finger tapping, and DBS-by-task interactions (eg,  $BTX_{[tapping > rest]} > DBS_{[tapping > rest]}$ ) were estimated. The results of task and group comparisons are reported for  $P < 0.05$ , family-wise error (FWE)-corrected at the peak level and a minimum cluster size of 20 voxels; for interaction contrasts,  $P < 0.05$  with cluster-level FWE correction was considered significant. Regions were identified using the automated anatomical labeling atlas.<sup>46</sup>

Individual uptake values in peak voxels of significant clusters detected by group comparisons were extracted using the SPM toolbox MarsBaR (<http://marsbar.sourceforge.net/>), and the values from the 3 scans per condition per participant were averaged and plotted for detection of potential outliers.

## Results

### Effect of Motion

For quality control, motor activation (contrast: tapping > rest) was tested in individual participants for each scanning session, confirming that every patient showed activation of the sensorimotor cortex contralateral to the hand performing the task. Peak SPM



**FIG. 1.** Effect of finger tapping. Motor activation in patients with botulinum toxin therapy (yellow), globus pallidus internus–deep brain stimulation OFF (purple), and globus pallidus internus–deep brain stimulation ON (light blue) on an MNI space template. For cluster details, see Table 2.

$T$  values of individual SMC clusters detected in the single-subject analysis are reported in Table 1. Tapping-associated brain activity was then assessed within each group and DBS state ( $BTX_{\text{tapping}} > BTX_{\text{rest}}$ ;

$ON_{\text{tapping}} > ON_{\text{rest}}$ ;  $OFF_{\text{tapping}} > OFF_{\text{rest}}$ ). At a threshold of  $P < 0.05$  (peak-level FWE corrected), both groups showed highly significant activation of the contralateral primary motor cortex and SMA, but only

**TABLE 2.** Motion-associated activation in each group

Group/DBS State	Areas Activated	Cluster Size, voxels	MNI Space Coordinates $x\ y\ z$	Statistics	
				$z$	$P$
BTX	Contralateral M1, S1, bilateral SMA	4365	38 -18 60	$> 8$	$< 1 \times 10^{-10}$
	Ipsilateral cerebellar lobules 4–6, vermis 4–6	681	-24 -56 -24	7.81	$5 \times 10^{-10}$
	Contralateral supramarginal gyrus, superior temporal gyrus, rolandic operculum	163	58 -24 20	7.02	$2 \times 10^{-7}$
	Ipsilateral frontal and rolandic operculum, insula	58	-48 6 4	5.70	$4 \times 10^{-4}$
	Contralateral putamen, insula	33	36 0 2	5.59	0.001
	Contralateral supramarginal gyrus	82	64 -36 34	5.46	0.001
	Ipsilateral supramarginal gyrus, superior temporal gyrus	53	-62 -40 22	5.07	0.009
DBS OFF state	Contralateral M1, S1	1163	42 -24 62	7.76	$8 \times 10^{-10}$
	Contralateral SMA	22	10 -4 56	5.14	0.007
DBS ON state	Contralateral M1, S1	974	42 -18 62	7.60	$3 \times 10^{-9}$
	Ipsilateral SMA	119	-6 -6 66	6.07	$5 \times 10^{-5}$
	Contralateral SMA	120	10 2 66	5.68	$4 \times 10^{-4}$

Motion-associated activation (tapping > rest) in each group, separately for DBS ON and OFF states. BTX patients activated more regions during finger tapping than patients with DBS. Peak-level FWE-corrected  $P$  values and clusters of  $\geq 20$  voxels are reported. DBS, deep brain stimulation; BTX, botulinum toxin; SMA, supplementary motor area.

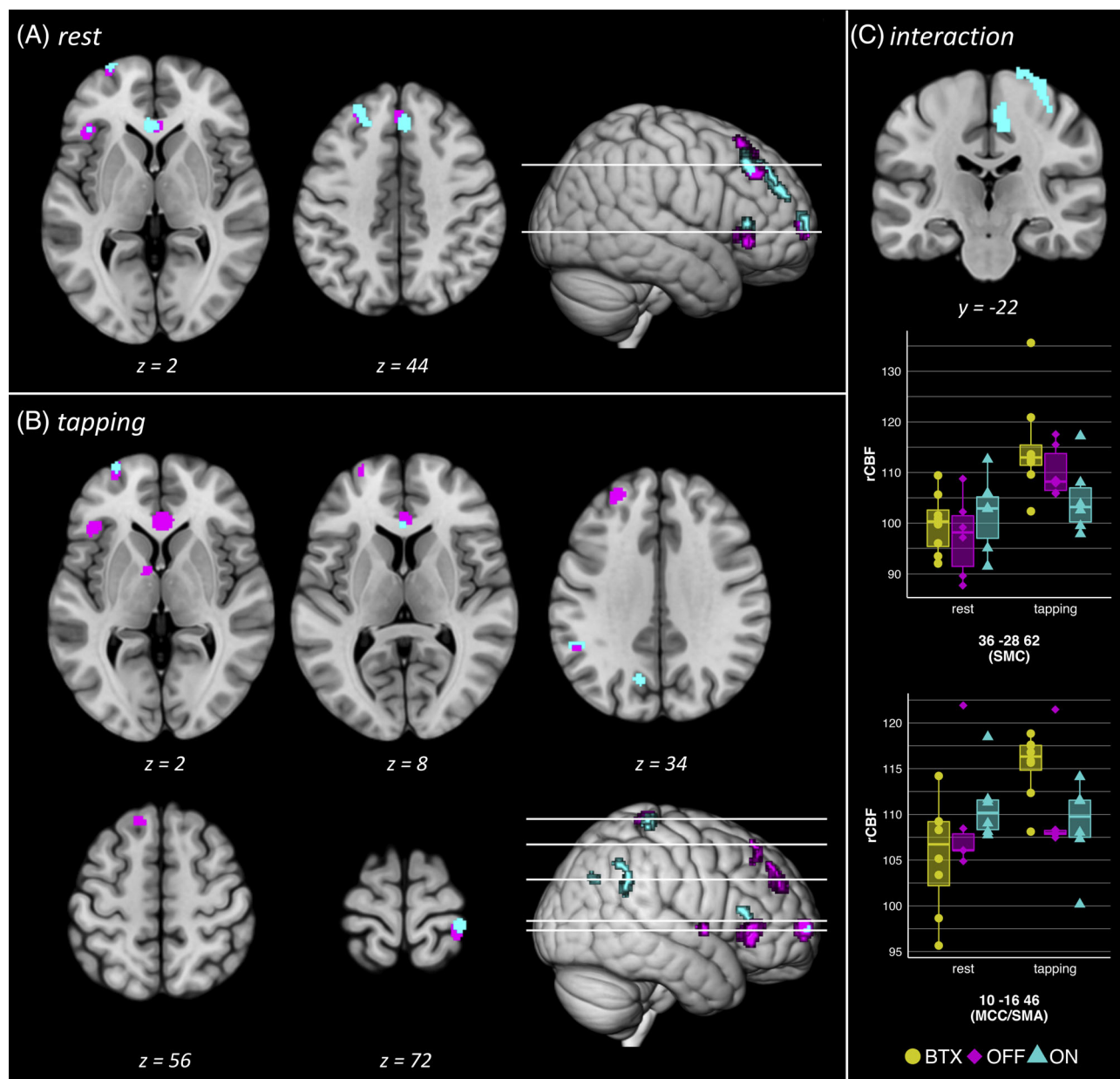
patients with BTX additionally activated the ipsilateral cerebellum, bilateral IPC (supramarginal gyrus), operculum, superior temporal gyrus, and insula as well as the contralateral putamen (see Fig. 1, Table 2).

### Effect of GPi-DBS With Stimulation ON and OFF

The DBS patients were compared with the BTX control group in the ON and OFF states, separately for the 2 conditions task and rest (eg,  $BTX_{rest} > ON_{rest}$ ;  $BTX_{tapping} > OFF_{tapping}$ ;  $P < 0.05$  peak-level FWE

corrected). The results are depicted in Figure 2 and detailed in Table 3, and individual participants' rCBF in peak voxels of each cluster is plotted in Supplementary Figure S1, which demonstrates that none of the results were primarily driven by outliers.

When resting rCBF was compared between DBS ON and BTX, lower activity in several prefrontal regions was observed in the DBS patients. These included the bilateral ACC and dorsal medial prefrontal cortex as well as the frontal pole, DLPFC, and triangular gyrus of the ipsilateral hemisphere. Interestingly, the same regions were still found when the BTX patients were compared with DBS



**FIG. 2.** Reduced rCBF in the ON and OFF state. Reductions in rCBF in the OFF state (purple) and ON state (light blue) were more similar at rest (A) than during tapping (B). The group-by-task interaction (C) showed lower activation of SMC and MCC/SMA, which was significant only in the ON state. BTX, botulinum toxin; MCC, middle cingulate cortex; rCBF, regional cerebral blood flow; SMA, supplementary motor area; SMC, primary sensorimotor cortex.



OFF at rest, with similar between-group statistics (see Table 3). An area of significantly increased rCBF at rest was only detected in the ON state, where a small region in the mid-cingulate cortex (MCC) and SMA of the contralateral hemisphere was more active (coordinates: 14 -12 44,  $z = 5.53$ ,  $P = 0.001$  peak-level FWE corrected, 28 voxels). Also at rest, in both the ON and OFF states, increased ipsilateral cerebellar activity was noted but did not reach the statistical threshold.

During finger tapping, DBS patients showed reduced activity in the contralateral primary sensorimotor cortex and ipsilateral IPC. Again, these reductions were still present after DBS had been paused for 12 hours (see Table 3). In contrast, other group differences observed in the active condition were more dependent on DBS states: activity in the precuneus was reduced during finger tapping only with DBS ON, and only in the OFF state a

cluster in the ipsilateral thalamus was less active than in BTX. The pattern of reduced prefrontal activity, which was similar in ON and OFF states at rest, was almost unchanged during finger tapping in the OFF state, but less pronounced in the ON state (see Fig. 2 and Table 3). No increase in activity was seen in DBS patients during task execution.

When the ON and OFF states were compared directly (eg,  $\text{OFF}_{\text{rest}} < \text{ON}_{\text{rest}}$ ;  $P < 0.05$  peak-level FWE corrected), no significant differences were found.

### Interaction Between Task and Group

The contrast  $\text{BTX}_{(\text{tapping} > \text{rest})} > \text{DBS ON}_{(\text{tapping} > \text{rest})}$  revealed that tapping-associated rCBF increases in the SMC, MCC, and SMA were higher in the BTX patients (see Fig. 2C; statistics [cluster-level FWE corrected]:

**TABLE 3.** Regions with decreased rCBF in DBS

Region/Contrast	BTX > OFF (Rest)	BTX > ON (Rest)	BTX > OFF (Tapping)	BTX > ON (Tapping)
Ipsilateral triangular gyrus	-42 26 0 $z = 5.82$ $P < 0.001$ 69 voxels	-42 26 0 $z = 5.18$ $P = 0.005$ 21 voxels	-42 26 0 $z = 6.00$ $P < 0.001$ 94 voxels	
Ipsilateral frontal pole	-28 64 6 $z = 5.41$ $P = 0.002$ 58 voxels	-26 68 6 $z = 5.57$ $P = 0.001$ 66 voxels	-28 62 4 $z = 5.64$ $P = 0.001$ 78 voxels	-28 66 2 $z = 5.27$ $P = 0.003$ 23 voxels
Ipsilateral DLPFC	-26 36 46 $z = 5.25$ $P = 0.006$ 52 voxels	-26 40 42 $z = 5.46$ $P = 0.001$ 159 voxels	-26 48 30 $z = 6.06$ $P < 0.001$ 140 voxels	
Bilateral dorsal mPFC <sup>a</sup>	4 36 40 $z = 5.15$ $P = 0.004$ 196 voxels	4 30 44 $z = 5.43$ $P = 0.002$ 112 voxels	-12 32 56 $z = 5.10$ $P = 0.008$ 69 voxels	
Bilateral ACC	2 28 0 $z = 5.28$ $P = 0.003$ 67 voxels	-4 30 4 $z = 5.70$ $P < 0.001$ 71 voxels	4 30 0 $z = 5.86$ $P < 0.001$ 187 voxels	0 26 14 $z = 5.21$ $P = 0.005$ 38 voxels
Ipsilateral thalamus			-8 0 2 $z = 5.05$ $P = 0.010$ 34 voxels	
Ipsilateral precuneus				-14 -68 34 $z = 5.28$ $P = 0.003$ 24 voxels
Ipsilateral IPC			-52 -50 32 $z = 5.10$ $P = 0.008$ 22 voxels	-52 -48 30 $z = 5.83$ $P < 0.001$ 111 voxels
Contralateral SMC			34 -36 72 $z = 5.50$ $P = 0.001$ 52 voxels	38 -34 70 $z = 5.43$ $P = 0.002$ 58 voxels

MNI space coordinates ( $x$   $y$   $z$ ),  $z$  score, peak-level family-wise error-corrected  $P$  value and number of voxels of significant clusters.

<sup>a</sup>In the contrast  $\text{BTX}_{(\text{tapping} > \text{OFF}_{\text{tapping}})}$  this cluster was ipsilateral and included the superior frontal gyrus.

rCBF, regional cerebral blood flow; DBS, deep brain stimulation; BTX, botulinum toxin; DLPFC, dorsolateral prefrontal cortex; mPFC, medial prefrontal cortex; ACC, anterior cingulate cortex; IPC, inferior parietal cortex; SMC, primary sensorimotor cortex.

SMC coordinates: 36 -28 62,  $z = 4.76$ ,  $P = 0.006$ , 421 voxels; MCC/SMA coordinates: 10 -16 46,  $z = 5.08$ ,  $P = 0.003$ , 475 voxels). The group-by-task interaction was only significant in the ON state. In the OFF state, similar clusters were found in the same regions, but the effect was weaker and did not survive correction for multiple comparisons. Individual participants' rCBF in peak voxels of clusters resulting from the interaction contrast are plotted in Figure 2C.

## Discussion

Focal or segmental dystonia patients with long-term GPi-DBS and BTX treatment were directly compared for the first time in this study, revealing differences in brain activity between 2 effective treatment methods for the same disorder. DBS patients showed lower rCBF in sensorimotor areas (SMC, IPC) and recruited fewer regions during the performance of a simple motor task than BTX patients. In addition, several prefrontal areas, including the ACC, were less active in DBS. As discussed in the following sections, these results suggest that long-term GPi-DBS in focal and segmental isolated dystonia affects rCBF in a similar fashion as previously reported in other forms of dystonia and reduces pathological dystonia-related activity, potentially by reorganizing cortico-subcortical circuits.

### Normalization of Sensorimotor Cortical Activation

Our data revealed reduced rCBF in DBS patients during finger tapping in the primary sensorimotor cortex when compared with the non-DBS (BTX) control group in both ON and OFF states. In the DBS ON state, a group-by-task interaction showed attenuated task-associated activation, which was not seen in the OFF state. Sensorimotor cortex hyperactivity is often seen in dystonia, as suggested by findings of increased metabolism,<sup>47</sup> blood flow,<sup>17,19</sup> task-related activation,<sup>21</sup> loss of inhibition, and increased neural plasticity.<sup>48,49</sup> Bilateral GPi-DBS for dystonia has previously been associated with decreased task-related motor cortex activation<sup>3,37</sup> and rCBF at rest, when active stimulation (ON) was compared with the DBS OFF state.<sup>3,4,25</sup>

The inferior parietal cortex, a widely connected network hub that integrates multimodal information,<sup>21</sup> showed reduced activity during finger tapping ipsilateral to the moving hand in GPi-DBS. The IPC, too, is hyperactive in dystonia,<sup>17,21,25,26</sup> suggesting a normalized level of activity is induced by long-term GPi-DBS for focal and segmental dystonia, as was previously described in generalized dystonia.<sup>25</sup> In healthy participants, stimulation of the IPC elicits an unspecific intention to move,<sup>50</sup> highlighting its relevance for motion

preparation, which is assumed to be disturbed in dystonia.<sup>25,51</sup>

The MCC/SMA cluster was the only region with increased activity in GPi-DBS in this study, whereas task-related activation (ie, group-task interaction) in the same area was reduced. The mentioned meta-analysis<sup>21</sup> found that task activation was increased in MCC while a closely neighboring SMA cluster showed decreased activation when only patients with focal or segmental dystonia were included. Previous investigations of GPi-DBS in acquired dystonia reported reduced SMA activity at rest,<sup>3,4</sup> whereas in primary dystonia lower task-induced activation was mentioned in a case report and a pilot study.<sup>11,37</sup>

### GPi-DBS Reduces Activity in a Prefrontal Network

Patients with GPi-DBS showed markedly reduced rCBF in the bilateral ACC and dorsal medial prefrontal cortex as well as the ipsilateral DLPFC, triangular gyrus, and frontal pole when compared with patients with BTX therapy. Increased activity in several of these regions has repeatedly been associated with dystonia,<sup>17,18,26</sup> and a reduction of resting activity<sup>3,4,38</sup> or task activation<sup>11,25,37</sup> to more physiological levels in several prefrontal regions were reported before in GPi-DBS. In contrast to previous studies, group differences in this prefrontal network at rest remained unchanged after DBS was discontinued and during the tapping task were even more pronounced than in the ON state (see Table 3 and Fig. 2).

Nonmotor symptoms of dystonia and neuropsychiatric comorbidity have recently received increasing interest.<sup>16,52-54</sup> Depression and anxiety are among the most frequent comorbidities, and it has been pointed out that brain regions associated with these conditions, including the ACC and DLPFC, also have been implicated in dystonia.<sup>16</sup> Interactions between sensorimotor and limbic networks have been suspected as a possible link.<sup>55</sup> Particularly the anterior cingulate gyrus, which previously showed hypermetabolism,<sup>27</sup> increased blood flow,<sup>18,26</sup> and motor task-related activation<sup>56</sup> in dystonia, is highly involved in the processing of aversive stimuli, emotion regulation, and associated cognitive functions.<sup>57-59</sup> The association of neuroimaging findings with neuropsychiatric symptoms in dystonia has not been studied much, but in writer's cramp, the ACC was more responsive to negative feedback than in controls.<sup>60</sup> A trend for reduced anxiety after GPi-DBS was reported in several studies, but improvements were not statistically significant.<sup>2,61,62</sup> The dorsolateral prefrontal cortex plays a role in self-initiated movements<sup>63</sup> and cognitive control of motor behavior<sup>64</sup> in healthy controls; however, these functions are mainly right lateralized, whereas as a result of flipping hemispheres



were mixed in the present study, therefore no final conclusions about the functional implications of reduced DLPFC activity in GPi-DBS can be drawn. The triangular gyrus also has side-specific functions (eg, Broca's area on the left hemisphere<sup>65</sup>), which cannot be related to the results of this study. Interestingly, a very similar prefrontal network, along with the IPC, was found in a meta-analysis of activations in go/no-go tasks.<sup>66</sup> One study reported postoperatively impaired Stroop test performance as an isolated cognitive change,<sup>67</sup> but reviews concluded that cognition is normal in dystonia before<sup>16</sup> and after GPi-DBS.<sup>53</sup>

### Long-Term Effects of GPi-DBS in Dystonia

In this study, effects of DBS, including changes in primary sensorimotor as well as higher order association areas, were generally still present after 12 hours DBS OFF. This observation is in contrast to previous imaging studies in GPi-DBS, where the effects were detected by comparing DBS ON and OFF states, whereas significant differences between GPi-DBS ON and OFF were not found in this cohort of focal and segmental dystonia patients. Possible reasons for this discrepancy may be related to (1) the extent of clinical symptoms, as the majority of previous findings were obtained in patients with generalized dystonia; (2) the fact that the examined hand was not affected by dystonia in our study; or (3) the time elapsed since DBS implantation. The longest previously reported average time since DBS surgery was 13 months<sup>38</sup> compared with 22 months on average in the present study. Stability in the OFF state may still increase after a long period of effective DBS, as suggested by studies reporting long-term follow-up after 3 years and later.<sup>5,34,36,68</sup> An influence of DBS duration<sup>34,69</sup> has been reported, and in an extended (48 hours) OFF state, the symptoms were related to changed cortical inhibition and plasticity.<sup>69</sup> After years of treatment, some patients remained clinically stable for a long time, in 1 case longer than 1 year.<sup>70,71</sup> The presence or absence of dystonia in the hand used for task execution may be relevant particularly concerning the differences found in sensorimotor activation.<sup>33</sup>

Although the effects of GPi-DBS on rCBF were relatively stable for 12 hours after stimulation was discontinued, there were signs of a slow reversal, particularly in motor regions. Significantly increased SMA activity at rest and group-by-task interaction of reduced tapping-related SMC activation were only found in the ON state, but did not reach significance with DBS OFF. Accordingly, peak rCBF values of clusters in SMC (tapping) and MCC/SMA (rest) extracted from OFF-state scans were in between those observed in the ON state and BTX (see Fig. 2C). Decreased rCBF in the IPC during tapping was still present, but the effect was weaker in the OFF state. These findings imply that after a

longer duration OFF DBS, the observed changes in sensorimotor activity may disappear.

### Strengths and Limitations

Overall, this study sheds new light on the effects of GPi-DBS in idiopathic focal and segmental dystonia. However, there are some methodological issues to consider. Although the patients in both groups had similar symptom severity and responded well to their respective treatments, this could only be judged by the distribution of symptoms and the clinical impression of movement disorder neurologists because Burke-Fahn-Marsden Dystonia Rating Scale scores were not available for the BTX patients. Healthy controls were not included because of ethical considerations. Nevertheless, the observed deactivation of the SMC, which was more pronounced in the ON state, strongly suggests a reduction of dystonia-related hyperactivity, which most likely underlies the improvement of dystonic symptoms due to GPi-DBS.

The number of participants was limited; however, existing PET imaging studies of DBS for dystonia have included between 1 and 6 DBS patients. To our knowledge, this is the first study dedicated to investigating the effect of GPi-DBS in isolated focal and segmental dystonia, providing valuable new insights into the mechanisms of GPi-DBS. An unaffected hand was examined to detect the direct effects of DBS on brain function while eliminating putative confounding effects of altered muscle activity.

The inclusion of a dystonic control group without DBS as implemented here constitutes a new approach in this line of research, whereas previous studies generally assumed that the OFF state represented the absence of DBS, thus not accounting for possible long-term effects. This was particularly relevant in our study because of the longer duration of DBS therapy.

### Outlook

Future investigations could compare patients with different durations of DBS treatment, ideally in a longitudinal design starting with a presurgical scan. Multi-centric approaches and data-sharing initiatives should be prioritized to increase sample sizes. The recurring findings of prefrontal alterations in dystonia require further research, in particular concerning their association with nonmotor symptoms and their contribution to the effect of GPi-DBS.

### References

1. Vidailhet M, Vercueil L, Houeto JL, et al. Bilateral deep-brain stimulation of the globus pallidus in primary generalized dystonia. *N Engl J Med* 2005;352:459–467.
2. Kupsch A, Benecke R, Muller J, et al. Pallidal deep-brain stimulation in primary generalized or segmental dystonia. *N Engl J Med* 2006;355:1978–1990.

3. Thobois S, Ballanger B, Xie-Brustolin J, et al. Globus pallidus stimulation reduces frontal hyperactivity in tardive dystonia. *J Cereb Blood Flow Metab* 2008;28:1127–1138.
4. Kefalopoulou Z, Paschali A, Markaki E, et al. Regional cerebral blood flow changes induced by deep brain stimulation in secondary dystonia. *Acta Neurochir (Wien)* 2010;152:1007–1014.
5. Volkmann J, Wolters A, Kupsch A, et al. Pallidal deep brain stimulation in patients with primary generalised or segmental dystonia: 5-year follow-up of a randomised trial. *Lancet Neurol* 2012;11:1029–1038.
6. Cif L, Vasques X, Gonzalez V, et al. Long-term follow-up of DYT1 dystonia patients treated by deep brain stimulation: an open-label study. *Mov Disord* 2010;25:289–299.
7. Volkmann J, Mueller J, Deuschl G, et al. Pallidal neurostimulation in patients with medication-refractory cervical dystonia: a randomised, sham-controlled trial. *Lancet Neurol* 2014;13:875–884.
8. Santos AF, Veiga A, Augusto L, Vaz R, Rosas MJ, Volkmann J. Successful treatment of blepharospasm by pallidal neurostimulation. *Mov Disord Clin Pract* 2016;3:409–411.
9. Reese R, Gruber D, Schoenecker T, et al. Long-term clinical outcome in meige syndrome treated with internal pallidum deep brain stimulation. *Mov Disord* 2011;26:691–698.
10. Neychev VK, Gross RE, Lehericy S, Hess EJ, Jinnah HA. The functional neuroanatomy of dystonia. *Neurobiol Dis* 2011;42:185–201.
11. Niethammer M, Carbon M, Argyelan M, Eidelberg D. Hereditary dystonia as a neurodevelopmental circuit disorder: evidence from neuroimaging. *Neurobiol Dis* 2011;42:202–209.
12. Zoons E, Booij J, Nederveen AJ, Dijk JM, Tijssen MAJ. Structural, functional and molecular imaging of the brain in primary focal dystonia—a review. *NeuroImage* 2011;56:1011–1020.
13. Lehericy S, Tijssen MAJ, Vidalhet M, Kaji R, Meunier S. The anatomical basis of dystonia: current view using neuroimaging. *Mov Disord* 2013;28:944–957.
14. Battistella G, Termsarasab P, Ramdhani RA, Fuerstinger S, Simonyan K. Isolated focal dystonia as a disorder of large-scale functional networks. *Cereb Cortex* 2015;27:1203–1215.
15. Jinnah HA, Berardelli A, Comella C, et al. The focal dystonias: current views and challenges for future research: unanswered questions in focal dystonias. *Mov Disord* 2013;28:926–943.
16. Stamelou M, Edwards MJ, Hallett M, Bhatia KP. The non-motor syndrome of primary dystonia: clinical and pathophysiological implications. *Brain* 2012;135:1668–1681.
17. Carbon M, Argyelan M, Habeck C, et al. Increased sensorimotor network activity in DYT1 dystonia: a functional imaging study. *Brain* 2010;133:690–700.
18. Playford ED, Passingham RE, Marsden CD, Brooks DJ. Increased activation of frontal areas during arm movement in idiopathic torsion dystonia. *Mov Disord* 1998;13:309–318.
19. Oergren T, Stone-Elander S, Ingvar M. Cerebral and cerebellar activation in correlation to the action-induced dystonia in writer's cramp. *Mov Disord* 1998;13:497–508.
20. Lerner A, Shill H, Hanakawa T, Bushara K, Goldfine A, Hallett M. Regional cerebral blood flow correlates of the severity of writer's cramp symptoms. *NeuroImage* 2004;21:904–913.
21. Løkkegaard A, Herz DM, Haagenen BN, Lorentzen AK, Eickhoff SB, Siebner HR. Altered sensorimotor activation patterns in idiopathic dystonia—an activation likelihood estimation meta-analysis of functional brain imaging studies. *Hum Brain Mapp* 2016;37:547–557.
22. Delnooz CCS, Pasman JW, Beckmann CF, van de Warrenburg BPC. Task-free functional MRI in cervical dystonia reveals multi-network changes that partially normalize with botulinum toxin. *PLoS ONE* 2013;8:e62877.
23. Dresel C, Haslinger B, Castrop F, Wohlschlaeger AM, Ceballos-Baumann AO. Silent event-related fMRI reveals deficient motor and enhanced somatosensory activation in orofacial dystonia. *Brain* 2006;129:36–46.
24. Nelson AJ, Blake DT, Chen R. Digit-specific aberrations in the primary somatosensory cortex in writer's cramp. *Ann Neurol* 2009;66:146–154.
25. Detante O, Vercueil L, Thobois S, et al. Globus pallidus internus stimulation in primary generalized dystonia: a H215O PET study. *Brain* 2004;127:1899–1908.
26. Schrag AE, Mehta AR, Bhatia KP, et al. The functional neuroimaging correlates of psychogenic versus organic dystonia. *Brain* 2013;136:770–781.
27. Galardi G, Perani D, Grassi F, et al. Basal ganglia and thalamo-cortical hypermetabolism in patients with spasmodic torticollis. *Acta Neurol Scand* 1996;94:172–176.
28. Obermann M, Vollrath C, de Greiff A, et al. Sensory disinhibition on passive movement in cervical dystonia. *Mov Disord* 2010;25:2627–2633.
29. Ceballos-Baumann AO, Passingham RE, Marsden CD, Brooks DJ. Motor reorganization in acquired hemidystonia. *Ann Neurol* 1995;37:746–757.
30. Bradley D, Whelan R, Kimmich O, et al. Temporal discrimination thresholds in adult-onset primary torsion dystonia: an analysis by task type and by dystonia phenotype. *J Neurol* 2012;259:77–82.
31. O'Dwyer JP, O'Riordan S, Saunders-Pullman R, et al. Sensory abnormalities in unaffected relatives in familial adult-onset dystonia. *Neurology* 2005;65:938–940.
32. Espay AJ, Morgante F, Purzner J, Gunraj CA, Lang AE, Chen R. Cortical and spinal abnormalities in psychogenic dystonia. *Ann Neurol* 2006;59:825–834.
33. Pirio Richardson S, Altenmüller E, Alter K, et al. Research priorities in limb and task-specific dystonias. *Front Neurol* 2017;8:170.
34. Cif L, Ruge D, Gonzalez V, et al. The influence of deep brain stimulation intensity and duration on symptoms evolution in an OFF stimulation dystonia study. *Brain Stim* 2013;6:500–505.
35. Ruge D, Tisch S, Hariz MI, et al. Deep brain stimulation effects in dystonia: time course of electrophysiological changes in early treatment. *Mov Disord* 2011;26:1913–1921.
36. Ruge D, Cif L, Limousin P, et al. Longterm deep brain stimulation withdrawal: clinical stability despite electrophysiological instability. *J Neurol Sci* 2014;342:197–199.
37. Kumar R, Dagher A, Hutchison WD, Lang AE, Lozano AM. Globus pallidus deep brain stimulation for generalized dystonia: clinical and PET investigation. *Neurology* 1999;53:871–874.
38. Yianni J, Bradley K, Soper N, et al. Effect of GPi DBS on functional imaging of the brain in dystonia. *J Clin Neurosci* 2005;12:137–141.
39. Opavský R, Hlušík P, Otruba P, Kažovský P. Sensorimotor network in cervical dystonia and the effect of botulinum toxin treatment: a functional MRI study. *J Neurol Sci* 2011;306:71–75.
40. Nevrlý M, Hlušík P, Hok P, Otruba P, Tüdös Z, Kažovský P. Changes in sensorimotor network activation after botulinum toxin type A injections in patients with cervical dystonia: a functional MRI study. *Exp Brain Res* 2018;236:2627–2637.
41. Ceballos-Baumann AO, Sheean G, Passingham RE, Marsden CD, Brooks DJ. Botulinum toxin does not reverse the cortical dysfunction associated with writer's cramp. A PET study. *Brain* 1997;120:571–582.
42. Marsh WA, Monroe DM, Brin MF, Gallagher CJ. Systematic review and meta-analysis of the duration of clinical effect of onabotulinumtoxinA in cervical dystonia. *BMC Neurol* 2014;14:91.
43. Ballanger B, Lozano AM, Moro E, et al. Cerebral blood flow changes induced by pedunculopontine nucleus stimulation in patients with advanced Parkinson's disease: a [(15)O] H<sub>2</sub>O PET study. *Hum Brain Mapp* 2009;30:3901–3909.
44. Conway CR, Sheline YI, Chibnall JT, George MS, Fletcher JW, Mintun MA. Cerebral blood flow changes during vagus nerve stimulation for depression. *Psychiatry Res* 2006;146:179–184.
45. Friston KJ, Frith CD, Liddle PF, Frackowiak RSJ. Comparing functional (PET) images: the assessment of significant change. *J Cereb Blood Flow Metab* 1991;11:690–699.
46. Tzourio-Mazoyer N, Landeau B, Papathanassiou D, et al. Automated anatomical labeling of activations in SPM using a macroscopic anatomical parcellation of the MNI MRI single-subject brain. *NeuroImage* 2002;15:273–289.

47. Lalli S, Piacentini S, Franzini A, et al. Epidural premotor cortical stimulation in primary focal dystonia: clinical and  $^{18}$  F-fluoro deoxyglucose positron emission tomography open study: epidural premotor cortical stimulation in dystonia. *Mov Disord* 2012;27:533–538.
48. Quartarone A, Sant'Angelo A, Battaglia F, et al. Enhanced long-term potentiation-like plasticity of the trigeminal blink reflex circuit in blepharospasm. *J Neurosci* 2006;26:716–721.
49. Quartarone A, Hallett M. Emerging concepts in the physiological basis of dystonia. *Mov Disord* 2013;28:958–967.
50. Desmurget M, Sirigu A. Conscious motor intention emerges in the inferior parietal lobule. *Curr Opin Neurobiol* 2012;22:1004–1011.
51. Perruchoud D, Murray MM, Lefebvre J, Ionta S. Focal dystonia and the Sensory-Motor Integrative Loop for Enacting (SMILE). *Front Hum Neurosci* 2014;8. <https://doi.org/10.3389/fnhum.2014.00458>
52. Smit M, Kuiper A, Han V, et al. Psychiatric co-morbidity is highly prevalent in idiopathic cervical dystonia and significantly influences health-related quality of life: results of a controlled study. *Parkinsonism Relat Disord* 2016;30:7–12.
53. Eggink H, Szuflik S, Coenen MA, van Egmond ME, Moro E, Tijssen MAJ. Non-motor effects of deep brain stimulation in dystonia: a systematic review. *Parkinsonism Relat Disord* 2018;55:26–44.
54. Steinlechner S, Hagenah J, Rumpf H-J, et al. Associations of specific psychiatric disorders with isolated focal dystonia, and monogenic and idiopathic Parkinson's disease. *J Neurol* 2017;264:1076–1084.
55. Muntz AG, Koehler PJ. How psychogenic is dystonia? Views from past to present. *Brain* 2010;133:1552–1564.
56. Baker RS, Andersen AH, Morecraft RJ, Smith CD. A functional magnetic resonance imaging study in patients with benign essential blepharospasm. *J Neuro-Ophthalmol* 2003;23:11–15.
57. Veit R, Flor H, Erb M, et al. Brain circuits involved in emotional learning in antisocial behavior and social phobia in humans. *Neurosci Lett* 2002;328:233–236.
58. Jahn A, Nee DE, Alexander WH, Brown JW. Distinct regions within medial prefrontal cortex process pain and cognition. *J Neurosci* 2016;36:12385–12392.
59. Stevens FL, Hurley RA, Taber KH. Anterior cingulate cortex: unique role in cognition and emotion. *J Neuropsychiatry Clin Neurosci* 2011;23:121–125.
60. Zeuner KE, Knutzen A, Granert O, et al. Altered brain activation in a reversal learning task unmasks adaptive changes in cognitive control in writer's cramp. *NeuroImage Clin* 2015;10:63–70.
61. Hälbig TD, Gruber D, Kopp UA, Schneider G-H, Trottenberg T, Kupsch A. Pallidal stimulation in dystonia: effects on cognition, mood, and quality of life. *J Neurol Neurosurg Psychiatry* 2005;76:1713–1716.
62. Meoni S, Zurowski M, Lozano AM, et al. Long-term neuropsychiatric outcomes after pallidal stimulation in primary and secondary dystonia. *Neurology* 2015;85:433–440.
63. Jenkins IH, Jahanshahi M, Jueptner M, Passingham RE, Brooks DJ. Self-initiated versus externally triggered movements II. The effect of movement predictability on regional cerebral blood flow. *Brain* 2000;123:1216–1228.
64. Cieslik EC, Zilles K, Caspers S, et al. Is there “one” DLPFC in cognitive action control? Evidence for heterogeneity from co-activation-based parcellation. *Cereb Cortex* 2013;23:2677–2689.
65. Flinker A, Korzeniewska A, Shestuyk AY, et al. Redefining the role of Broca's area in speech. *Proc Natl Acad Sci U S A* 2015;112:2871–2875.
66. Simmonds DJ, Pekar JJ, Mostofsky SH. Meta-analysis of go/no-go tasks demonstrating that fMRI activation associated with response inhibition is task-dependent. *Neuropsychologia* 2008;46:224–232.
67. Huh R, Song I-U, Chung M. Neuropsychological consequences of pallidal deep brain stimulation altering brain networks. *J Clin Neurosci* 2018;54:50–56.
68. Grabli D, Ewencyk C, Coelho-Braga M-C, et al. Interruption of deep brain stimulation of the globus pallidus in primary generalized dystonia. *Mov Disord* 2009;24:2363–2369.
69. Ruge D, Cif L, Limousin P, et al. Shaping reversibility? Long-term deep brain stimulation in dystonia: the relationship between effects on electrophysiology and clinical symptoms. *Brain* 2011;134:2106–2115.
70. Cheung T, Zhang C, Rudolph J, Alterman RL, Tagliati M. Sustained relief of generalized dystonia despite prolonged interruption of deep brain stimulation. *Mov Disord* 2013;28:1431–1434.
71. Hebb MO, Chiasson P, Lang AE, Brownstone RM, Mendez I. Sustained relief of dystonia following cessation of deep brain stimulation. *Mov Disord* 2007;22:1958–1962.

## Supporting Data

Additional Supporting Information may be found in the online version of this article at the publisher's web-site.